




Should I refer? - guidance to dentists

A Guide to referring to a Specialist

'Malocclusion, like caries and periodontal disease, creeps up on its victims slowly... and we have an ethical duty to detect and inform.'

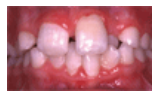How does a very busy general dental practitioner detect such a malocclusion? The key is to have a quick and easy method of clinical orthodontic examination available. Figure 1. gives an example of a simple examination.

Figure 1: A simple clinical orthodontic examination.

Make a note of:		Comments:
1. The skeletal discrepancy A and B points are the deepest points on the maxillary and mandibular profiles respectively.		<ul style="list-style-type: none"> • Seat the patient in the upright position, with the head in a natural posture (not tipped back or down). • Severe skeletal class II and III patterns are noted readily • To detect smaller discrepancies, palpate A and B points with the forefinger and middlefinger
2. The soft tissue pattern		<ul style="list-style-type: none"> • The lips at rest may be competent or incompetent
3. The presence of habits		<ul style="list-style-type: none"> • Thumb and finger sucking habits should be noted
4. The teeth present clinically		<ul style="list-style-type: none"> • Count the teeth • Note ectopic, unerupted or missing teeth
5. The occlusion in intercuspal position		<ul style="list-style-type: none"> • Measure the overjet • Note the overbite. Is it normal, increased or decreased? • Note any centreline shifts • Note the buccal segments (class I, II or III) • Is there crowding or spacing? • Are there any crossbites?
6. The occlusion in retruded contact position		<ul style="list-style-type: none"> • Is there a premature contact? • Is there a displacement ?

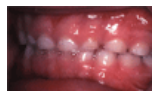You have done your orthodontic examination. Before referring you need to know what is normal. Which aspects of a potential malocclusion may correct spontaneously? Which aspects may not? Here are some useful pointers:

Normal aspects of the functional deciduous dentition (2.5 to 6 years)



- Spacing between deciduous incisors
- Flush distal surfaces of second deciduous molars

Eruption of the permanent dentition (6 to 13 years)

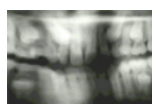

- Mild crowding in the lower labial segment
- median diastema

Figure 3: Canine impaction or pathology.

Permanent maxillary canines should be palpable buccally by 8-10 years of age. If they cannot be palpated by 10 years, alarm bells should sound. Malposition and damage to the roots of adjacent teeth are the main risks. Interceptive extraction of upper deciduous canines is an option often considered by orthodontists to manage canine malposition. However, early diagnosis is important if this option is to be used and space maintenance may also be needed. What should you do?

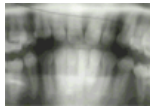
1. If, from palpation, palatal ectopia is suspected appropriate radiographs (for example, horizontal parallax) will be needed to confirm the diagnosis and to check for possible pathology.



2. Onward referral to a specialist orthodontist for advice on management is

appropriate if any abnormality is detected or suspected.

3. If the permanent canine is palatally impacted, extraction of the deciduous canine between ages 10 & 13 years is indicated. This has been shown to result in normalisation of such canines in 65%-91% of cases.



4. Do not extract deciduous canines where your parallax technique has shown the permanent canine to be buccally displaced or in the line of the arch. Extraction will lead to space loss and a deciduous molar/lateral incisor contact.

5. If in doubt, refer to a specialist.

Related Links

[Links to other information for dentists](#)A brief compendium for practitioners

©2012 British Orthodontic Society

Built on [Cubik](#)

Registered Charity Number 1073464. The BOS is a Company Limited by Guarantee. Registered in England and Wales. Company Number 03695486.